MYOCARDIAL FIBROSIS IN FORENSIC PATHOLOGY

Madalina Maria Diac[2], A. Knieling[1,2*], Tatiana Iov[1], D.A. Chiran[3], C.I. Stan[3*], Diana Bulgaru Iliescu[1,2]

1. Institute of Legal Medicine, Iasi
University of Medicine and Pharmacy "Grigore T. Popa", Iaşi,
Faculty of Medicine
2. Department of Forensic Sciences,
3. Department of Morpho-Functional Sciences I

MYOCARDIAL FIBROSIS IN FORENSIC PATHOLOGY (Abstract): Introduction: In the last years, throughout the world, the cardio-vascular pathology has a massive and continuous growth, with an increased gravity due to the lowering of the age of patients affected by this type of illness. Objectives: The main objective is reviewing the medico-legal cases with cardio-vascular pathology encountered by the authors in the 2015-2018 interval, with confirmation and positive appreciation of the growing incidence of this pathology, decreasing the age threshold and other medico-legal aspects, macroscopical and histopathological. Material and method: The following paper evaluates the cases of deaths due to myocardial fibrosis, encountered in the activity of the authors, on a 4-years period (2015-2018), at the Institute of Legal Medicine Iasi, Romania. Results: Out of a total of 374 medico-legal autopsies performed by the authors in the 2015-2018 period at the Institute of Legal Medicine Iasi, 80 deaths were attributed to myocardial fibrosis. Conclusions: Although the medical world is trying, on a global scale, to prevent cardio-vascular diseases by means of educational programs, encouraging periodic medical check-ups and innovative therapies, the incidence of this pathology is continuously growing, affecting increasingly younger patients. This review of the medico-legal cases encountered by the authors aims to confirm the ascending trend of cardio-vascular disease incidence and to raise attention to this issue. **Key words**: MYOCARDIAL FIBROSIS, CARDIO-VASCULAR PATHOLOGY, FORENSIC PRACTICE

INTRODUCTION

In recent years, globally, cardiovascular pathology is in a massive and exponential increase, and its severity is represented by the inversely proportional relationship between the increased prevalence of cardiovascular pathology and the decreasing age of patients. In this context, a continuous increase in the number of cardiac deaths is also observed, with cardiac dysfunction frequently associated with myocardial fibrosis.

Studies carried out in recent years note that the most common death caused by cardiovascular pathology occurs suddenly, patients having no knowledge ofcardiac pathological antecedentsor the appearance of a specific and conclusive pathologic cardiac symptomatology over a longer period of time.

Acute heart failure is a malignantă and fatal disease most often, representing a major public health problem globally. The incriminated mechanism is cardiac remodeling, which includes two aspects: cardiomyocytes lesions (myocardial hypertrophy, necrosis, apoptosis) and myocardial fibrosis (1, 2).

Myocardial fibrosis is an important part of cardiac remodeling, leading to heart failure and death. The incidence of cardiovascular pathology represented by myocardial fibrosis is 1-2% in developed countries and reaches up to 10% in people over 70 years of age (3, 4).

Cardiac fibrosis is a process characterized by accumulation of fibroblasts and excess deposits of extracellular proteins (extracellular matrix proteins) in myocardial interstitial, contributing to both systolic and diastolic function

in the presence of multiple cardiac physio pathological conditions, leading to an architectural disorganization of the heart (1, 4, 5).

It is known in the literature that myocardial tissue possesses a negligible regenerative capacity, so that the most extensive fibrotic remodeling of the ventricles is usually associated with sudden and high apoptosis of cardiomyocytes (acute cardiomycyte death). (2,6) Following the occurrence of an acute myocardial infarction, the sudden loss of a large number of cardiomyocytes triggers a chain of inflammatory reactions, the latter being based on the replacement of the dead myocardium with collagen tissue.

OBJECTIVE

In recent years, particular emphasis has been placed on the research of physiopatologia, the mechanisms involved as well as possible therapeutic options for treating or preventing the causes of sudden cardiac deaths. The major interest in this pathology is also motivated by the fact that cardiac fibrosis has profound and important consequences on myocardial function.

The main objective is to review the forensic casuistics of cardiovascular pathology encountered in the period 2015-2018 in the work of the authors, with confirmation and positive appreciation of the increase of this pathology, the age in decline of occurrence, as well as other macroscopic and anatomopathological forensic aspects.

MATERIAL AND METHOD

This paper is a descriptive study evaluating cases of death by cardiac fibrosis, found in the authors' work, over a period of 4 years (2015-2018)2018at the Institute of ForensicMedicine Iasi, Romania. Based on the analysis of the cases included in the study, the authors identified the age of deceased persons by myocardial fibrosis, the presence or absence of ethylic alcohol, as well as the highlighting of associated pathologies. The scientific literature, which presented myocardial fibrosis as the main subject, was also analysed in parallel.

RESULTS

The group consisted of 374 forensic necropsies performed by the authors between 2015 and 2018, of which 80 deaths were identified as a diagnosis of myocardial fibrosis.

DISCUSSION

In this study, the case was autopsied at the Institute of Forensic Medicine Iasi. The external examination was carried out, measuring the size of the deceased, the identification of the deceased persons, the signs of actual death, the absence of traces of violence, as well as other various signs that could have helped in the orientation to a possible diagnosis of a cardiac nature (nail cyanosis, perioral, the presence of anoxic spots that could provide clues of heart failure, in the absence of other asphyxia lesions, etc.), research in various signs of possible medical treatments (venous punctures, intubations, EKG paddles, defibrillators, pacemakers, etc.).

After the external examination of the body is carried out, the internal examination. The internal examination of the body was particularly monitored if the death was attributed to a cardiac cause or other causes of death, the nature of the cardiac cause, possible traumatic traces. Therefore in the case of sudden deaths, deaths, whose history is insignificant or absent, tas well as in the case of deceased patients who are not registered with a family doctor, on the internal examination, we excluded, firstof, the causes of non-cardiac death (cerebral, respiratory, hemorrhagic shock, septic shock, etc.), and in the second main step followed the detailed search of the cardiac causes of death.

In this respect, each examination of the heart was in accordance with the European Guide for the Investigation of Sudden Cardiac Deaths of the European Association of Cardiovascular Pathology (4, 6, 7).

The steps of the heart examination included :

- checking the integrity of the pericardium with the exploration of the pericardial cavity ;
- checking the correct anatomical positioning of the arteries with examination of the valves, their lumen.
- checking the coronary arteries (inspection, palpation, and performing transverse sections at distances of 3 mm for the purpose of checking the coronary lumen and the degree of obstruction).
- measuring and weighing the heart.
- measurement of the walls of the left ventricle, the interventional septum as well as the wall of the right ventricle.
- objectification of cardiac cavities (ventricular, atrial) ;
- biological sampling for the purpose of histopathological examination.

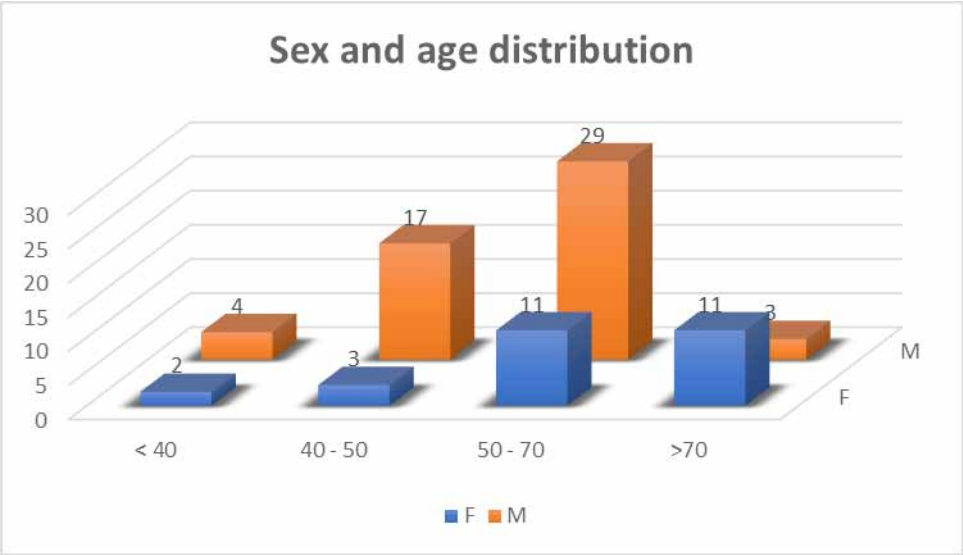

Fig. 1

As stipulated above, the cases included in this study presented as macroscopic aspects of the heart the following: various dimensions (the smallest size being 10/12/5 cm and the largest measured size being 24/1488/8 cm), weight also with multiple variations (the smallest weight of 340 g, the largest weight being 870 g), the dimensions of the right ventricle wall (0.2-0.8 cm), the interventional septum (0.8 – 1.5 cm), and the left ventricle wall (sizes between 1.3 cm and 2.4 cm). Each heart was examined by performing anatomological sections 1 cm apart. Each section was carefully examined on both sides, highlighting inthe thickness of the left ventricle myocardium, most commonly, on the anterior and septal face whitish areas in the form of discrete striae or large areas stretching over an area approximately 2 cm apart. Following macroscopic examination, macroscopic diagnoses (cardiomegaly, left ventricular hypertrophy, myocardial fibrosis, coronary atherosclerosis, etc.) were concluded.

Thefollowing explanations of the graphs presented above by exposing the results of the analysis of the cases included in the study.

A predominance of the male sex is observed among people who died by myocardial fibrosis with the highest share in the 50-70 age range, followed by the 40-50-year range. Thus, there is a significant decrease in the age of those affected by this cause of death. The number of female persons who were the subject of death by myocardial fibrosis was smaller, but not at a greater distance from the male sex; according to the graph the female sex is susceptible to death by myocardial fibrosis even under the age of 40, which becomes alarming, with cases under this age 2 female and 4 male persons respectively (fig. 1).

The literature mentions as a risk factor in the development of the process of atherosclerosis, which presents a high risk in the production of cardiovascular diseases, the consumption of ethyl alcohol, this being one of the important and aggravating social factors (6, 7, 8). In our study, it is noted that out of the total of 80 myocardial deaths on 61 necropsies there was no evidence in the samples taken by ethyl alcohol, or if it was revealed, there were small percentages, below 0.5g‰, which is insignificant. Of these 61 necropsies, 40 cases were represented by the male sex. The highlighting of ethyl alcohol was in the case of 19 necropsies, of which 3 persons were female, 16 males. In this respect, we can say in the cases presented, that ethyl alcohol was not a favourable factor for deaths by myocardial fibrosis, the pathogenic substrate being represented by myocardial fibrosis (fig. 2).

In clinical practice, cardiac remodeling is the equivalent of myocardial ischemia, pathology that translates electrocardiographically through various rhythm disorders, most often involved being ventricular fibrillation (5, 8). However, in forensic pathology, in the case of deceased persons, electrocardiography has no role; in these cases, the transposition of rhythm disorders into macroscopic aspects of the heart,

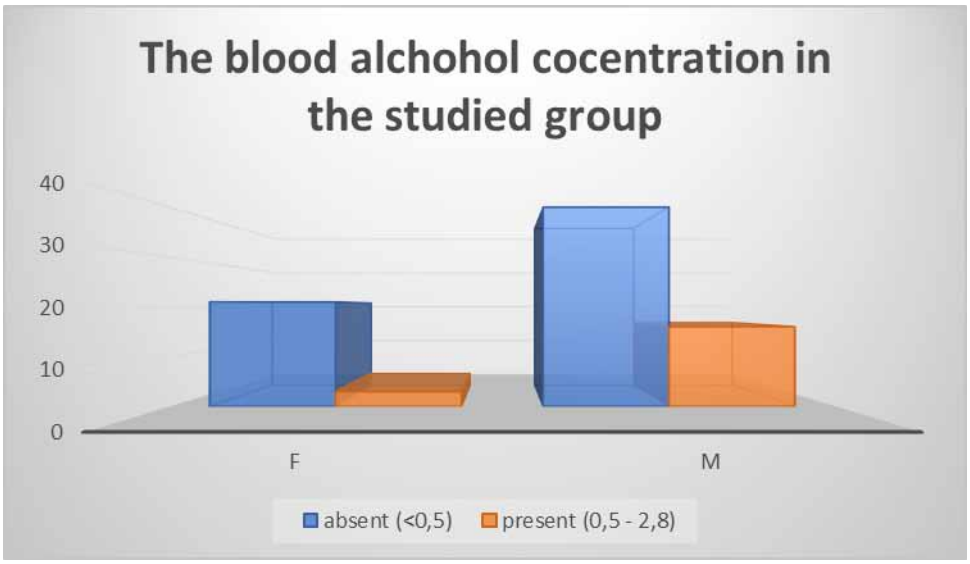

Fig. 2

aspects that may vary from the presence of simple, uncomplicated atherosclerosis, fibrosis (myocardial, epicardial) to macroscopic highlighting of myocardial infarction.

Also, the literature recognizes multiple other causes of myocardial fibrosis (old age and not only, hypertension, atherosclerosis, myocarditis, cardiomyopapathies, metabolic disorders, etc.) (3, 5, 7). However, in forensic pathology we encounter multiple cases of sudden cardiac deaths, with no history of known favorable associated pathologies, often the only macroscopic lesions shown at autopsy being coronary and/or aortic atherosclerosis and the presence of myocardial fibrosis (fig. 3).

One of the common factors of all cases with cardiovascular pathology and not only is the presence of coronary or aortic atherosclerosis, sometimes referred to as the Captain *of the Men of Death,* which is the main cause of sudden cardiac death in developed and modernsocieties. Ethiopathogenesis of coronary atherosclerosis has experienced multiple variations over the years (2, 7, 8, 9). In 1815, he was accused of atherosclerosis as inflammation. Subsequently, in 1856, the lipid hypothesis was developed by Rudolf Virchow in the process of the development of atherosclerosis, and in 1908 the hypothesis of inflammation associated with the infection was returned, by Sir William Osler. Currently, it is accepted that an initial lesion, whatever it may be (chemical, biochemical, mechanical or immunological) leads to endothelial dysfunction that acts as a trigger factor in the cascade of a whole and complex of cell, inflammatory and immunological reactions. After the formation of the atheroma, it develops to form atheroma plaques, which are deposited on the underside of the vessels, especially affecting the coronarys and along the way the large vessels (aorta). Coronary atherosclerosis can be focal with irregular plaques, varying in size and in the stenotic effect it induces on the coronary lumen, or it can be localized by offering the false appearance of free coronary lumen (1, 2, 5, 7).

The main complication of atherosclerosis is obstruction of the coronary lumen, which leads to insufficient vascularization of the myocardial territory related to the clogged coronary artery. Of the coronary arteries, the most commonly involved is the anterior descending coronary artery, the artery that irrigates the anterior wall of the left ventricle, and the interventional septum. Thus, the lesions resulting from obstruction of the lumen of the coronary artery, ischemia, necrosis and apoptosis, will be mostly highlighted on the anterior wall of the left ventricle and at the level of the interventional septum (8, 9, 10).

In this study, the authors conducted a classification of the associated pathologies encountered in necropsy. Thus, the pathologies associated with the presence of myocardial fibrosis were framed in cardiovascular pathologies, respiratory pathologies and other combined pathologies (fig. 3).

In cardiovascular pathologies, it was ob-

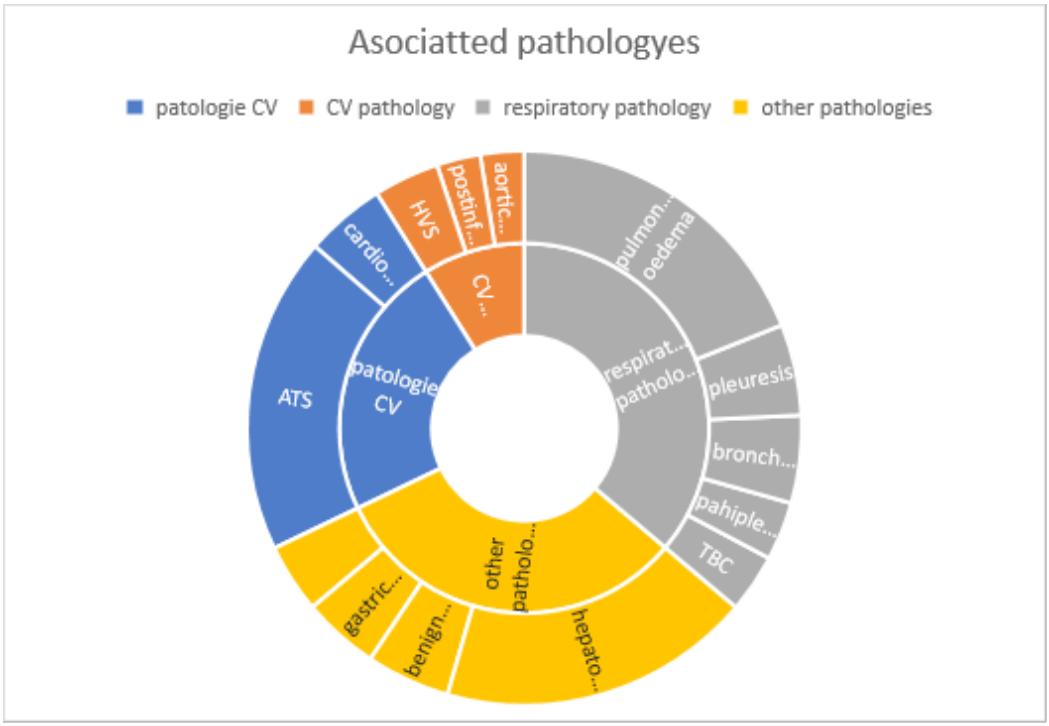

Fig. 3

served from the analysis of the cases included in the study, the significant presence of atherosclerosis, especially coronary atherosclerosis. The process of atherosclerosis was highlighted from small points and lipid streaks to the presence of simple and complicated atherosclerotic plaques that went as far as their confluence occupying the intimate of the aortic artery entirely. Other cardiovascular pathologies were represented by the presence of left ventricular hypertrophy (concentric and dilatative), cardiomegalia, as well as the presence of myocardial postinfarct scars.

Respiratory pathology is also complex, being most frequently occupied and predominant by acute pulmonary edema, followed at short distances by pahipleuritis, bilateral pleurisy, pulmonary cavities with caseum, as well as in some cases of pulmonary nodular formations.

The third category represented an association of other pathologies, being represented by hepatic pathology (hepatomegaly, hepatic steatosis, hepatic cirrhosis), renal pathologies (renal cysts, dilation of the pelvis – probable hydronephrosis, benign nephroangiosclerosis), gastric pathologies (gastric ulcers), and in the case of female persons pathologies of internal reproductive organs (uterine fibroma, ovarian cysts).

All pathologies encountered in necropsies performed in the cases involved in this study have been confirmed by histopathological examination, making the microscopic diagnosis of each organ fragment taken.

CONCLUSIONS

Despite numerous researches on myocardial fibrosis, the understanding of pathogenesis, the forensic implications, the mechanism for determining death remain limited. With regard to the physiology of myocardial fibrosis, further driving factors should be explored to improve diagnostic methods and identify therapeutic targets

Although the medical world is making efforts, globally, to prevent cardio-vascular diseases through information programs, encouraging regular medical checks and innovative therapies, the incidence of this pathology is constantly increasing, affecting younger and younger ages. This review of the forensic cases encountered by the authors is intended to confirm the increasing trend of the incident overa short period of cardio-vascular diseases and to draw attention tothis problem. New treatment methods, such as reducing heart fibrosis and reversing the reduction of the repolarization reserve without interfering with the coupling of excitation-contraction, support the future promise.

REFERENCES

1. Tong L, Deli S, Dong J et al. Current understanding of the pathophysiology of myocardial fibrosis and its quatitative assessment in heart failure. *Front Physiol*, 2017 ; 8(1).
2. Kong P, Panagiota C, Frangogiannis NG. The pathogenesis of cardiac fibrosis. *Cell Mol Life Sci*, 2014 ; 71(4) : 549-574.
3. Basso C, Calabrese F, Corrado D, Thiene G. Postmortem diagnosis in sudden cardiac death victims : macroscopic, microscopic and molecular findings. *Cardiovascular Research*, 2001 ; 50(2) : 290-300.
4. Yanci CW, Jessup M, Bozkurt M, Butler J, Casey DE, Drazner MH et al. ACCF/ACA guideline for the management of heart failure : executive summary a report of the American College of Cardiology Foundation/American Heart Association Task Force on practice guideline. *Circulation*, 2013 ; 128(1) : 1810-1852.
5. Heusch G, Libby P, Gersch B, Yellon D, Bohm M, Lopaschuk G et al. Cardiovascular remmodellng in coronary artery disease and heart failure. *Lancet*, 2014 ; 383 : 1933-1943.
6. Basso C, Burke M, Sheppard M, Van der Wal Allard. Guidelines for autopsy investigation of sudden cardiac death. *Virchows Arch*, 2008, 452 : 11-18.
7. Hara H, Takeda N, Komuro I. Pathophysiology and therapeutic potential of cardiac fibrosis. *Inflammation and Regeneration*, 2017, 27(13) : 1-10.
8. Krenning G, Zeisberg EM, Kalluri R. The origin of fibroblasts and mechanism of cardiac fibrosis. *J Cell Physhiol*, 2010, 225(3) : 631-637.
9. Reilly K. Cardiac Fibrosis : new treatments in cardiovascular medicine. *US Pharm*, 2015, 40(2) : 32-35.
10. Talman V, Ruskoaho H. Cardiac fibrosis in myocardial infarction – from repair and remodeling to regeneration. *Cell Tissue Res*, 2016, 365 : 563-581.

**** Corresponding author***

Anton Knieling
e-mail: anton.knieling@umfiasi.ro

Cristinel Ionel Stan
e-mail: cristinel.stan@umfiasi.ro