EVALUATION OF THE EFFICACY OF CARIES-REVEALING DYES IN DIFFERENTIATING BETWEEN INFECTED AND AFFECTED DENTIN DURING RESTORATIVE TREATMENT

Dorelia Lucia Călin
"Grigore T. Popa" University of Medicine şi Pharmacy, Iaşi
Discipline of Cariology and Restorative Odontotherapy

EVALUATION OF THE EFFICACY OF CARIES-REVEALING DYES IN DIFFERENTIATING BETWEEN INFECTED AND AFFECTED DENTIN DURING RESTORATIVE TREATMENT (Abstract): The aim of this study is to determine the advantages of using caries-revealing dyes in differentiating between infected and affected dentin during restorative treatment. Material and method: The patients selected for this study presented to the Discipline of Cariology and Restorative Odontotherapy within the Faculty of Dental Medicine, UMF „Gr. T. Popa" Iaşi, for a restorative treatment of carious lesions. Sable Seek dye was applied in order to differentiate the infected dentin from the affected one at the level of 26 molars and premolars that presented cavitary occlusal caries. Results: In all cases, the dye remained fixed in the cavity in the dentin, but the color intensity was different. Due to the difference in the intensity of the staining produced by the caries detector, it is possible to differentiate between the infected tissues with a much more intense staining (dark green) and the affected tissue with a less intense staining (light green). Conclusions: The contrast obtained by the caries developer can help to identify carious dentin if tactile discrimination is not available, and can be used as a complementary means of diagnosis.
Key-words: INFECTED DENTIN, AFFECTED DENTIN, CARIES DEVELOPER

INTRODUCTION

The main purpose of the treatment of dental caries is the removal of caries tissue, while preserving the structure of the tooth and maintaining the vitality of the pulp (1). The diagnosis of dental caries is often based on the color and consistency of the dentin, which is considered completely subjective, with low reproducibility (2).

Early detection and complete removal of tooth decay lesions play a key role in the treatment and prognosis of tooth decay. Today, there are many techniques for detecting dental caries such as direct visual inspection, indirect vision, auxiliary external illumination, transillumination, radiographs, direct digital radiography, electronic caries monitoring, caries activity tests and quantitative light-induced fluorescence. The techniques mentioned above are either not reliable or are too expensive for all dentists (3).

By traditional routine techniques, most infected dentin is not excavated, therefore the microorganisms present in the infected dentin are maintained after restoration. If nutrients are made available to these microorganisms either by marginal percolation or by diffusion from the pulp, these microorganisms will multiply and could lead to recurrence of the carious lesion (4). The difficulty of detecting infected carious dentin accurately and reliably by tactile and visual examination is not new (5).

A carious lesion consists of two layers: an outer, demineralized layer that is contaminated with bacteria and an inner layer that is partially demineralized without bacteria (6,7). Bacterial invasion appears to occur in the outer layer, but not in the inner layer, which has been described previously (6). However, it is not clinically easy to define the exact end point of caries removal (8). In the classic caries excavation, the operative tradition is to remove

the soaked dentin to remove the infected tissue and to leave the carious dentin which is „firm and leathery" where its removal could expose the pulp. However, the term „firm and leathery" is a subjective clinical assessment and may vary from operator to operator (9). Clinical differentiation between „caries-affected" dentin and „infected" dentin is one of the most difficult challenges encountered clinically (10,11).

Conventional means of detection are based on visual and tactile sensation (12), however, these methods are subjective and variable among practitioners. When carious tissue is removed with the help of hand pieces and burs, there is a tendency to over-excavate (13).

Different dyes are used to distinguish healthy hard tissues from decayed ones (14). The possibility of using caries-detecting dyes was first developed in the 1970s, when basic fuchsin staining was used as a guide for removing the outer layer of infected dentin in carious lesions (15). Histological dyes are color markers that have an affinity for the material on which it is applied. When the dye is applied to the surface of a tissue or material, it will be fixed in fibers, pores, or other structures. Paints absorb some wavelengths of light more than others, so color changes can be clearly distinguished (16). There are many dyes such as methyl red, alizarin, hydroxyquinoline 8, fluorescent dyes, carbolan green, coomassie blue, lissamine blue, 0.5% basic fuchsin, 1.0% acid red, which were used to detect caries and to help the clinician distinguish between affected and infected dentin during cavity preparation. There has always been concern about the safety of carcinogens in detecting carcinogenicity, and 1% acid red in propylene glycol has been introduced as a safe and effective alternative (4,5,14). Starr and Langenderfer (17) used caries detection dyes to improve the ability of dental residents to detect caries and demonstrated that the red acid dye is able to distinguish between infected and affected dentin thus helping the clinician in the process of caries removal.

At the dental chair during treatment it is not possible to confirm the presence or absence of residual carious dentine by precise methods, such as histological examination and scanning electron microscope or confocal laser scanning. The tactile sensation of the dentin by an expert can be considered as a standard technique in the oral cavity, but it is possible to overlook some areas with remaining decayed tissue (18).

Various caries detector dyes with different chemical formulas are commercially available today to help the dentist differentiate the softened dentin (Snoop caries detecting dyes, Pulpdent Corporation, Expose Caries Detector, Centrix, Caries detector, Kuraray America Inc., Caries Finder Detection Dye, Zest Dental Solutions etc). However, in the literature many authors are skeptical about the use of dyes because they have been found to be non-selective and result in excessive excavation of solid dentin (8,19). However, they are still marketed today, not being withdrawn.

The **aim** of this study is to determine the advantages of using caries-revealing dyes as a diagnostic tool in dental surgery in differentiating between infected and affected dentin during restorative treatment. The case study aims to highlight the advantages and disadvantages of using dye to detect decayed dentin, trying to motivate their use in dental practice.

MATERIAL AND METHOD

The patients chosen for this study presented themselves at the Discipline of Cariology and Restorative Odontotherapy of the Faculty of Dental Medicine, University of Medicine and Pharmacy „Gr. T. Popa" Iaşi for the conservative treatment of multiple caries. Sable Seek dye was applied in order to differentiate the infected dentin from the affected one at the level of 26 molars and premolars that presented cavitary occlusal caries. Sable Seek (produced by Ultradent, USA) is a dye-based caries detection agent, food grade, in a glycol-based solvent that stains degraded / infiltrated dentin in green, distinguishing it from the pulp and facilitating its location even in deep cavities (fig. 1).

Clinical examination of patients was performed after scaling and professional cleaning. Two examples of the procedure performed are presented below.

The first case was an 23-year-old patient CAR and she presented at the clinic for a dental check-up. Clinical examination showed good oral hygiene. Examination of dental surfaces was performed by conventional visual and radiological examination. Orthopantomography provided an overview of dental arches and dental lesions (fig.2).

The lower second premolar 45 showed a gray coloration in the mesial fossa and at the level of the proximal ridge (fig.3), being a clear

Fig. 1. Syringe with Sable Seek caries detector (Ultradent, USA)

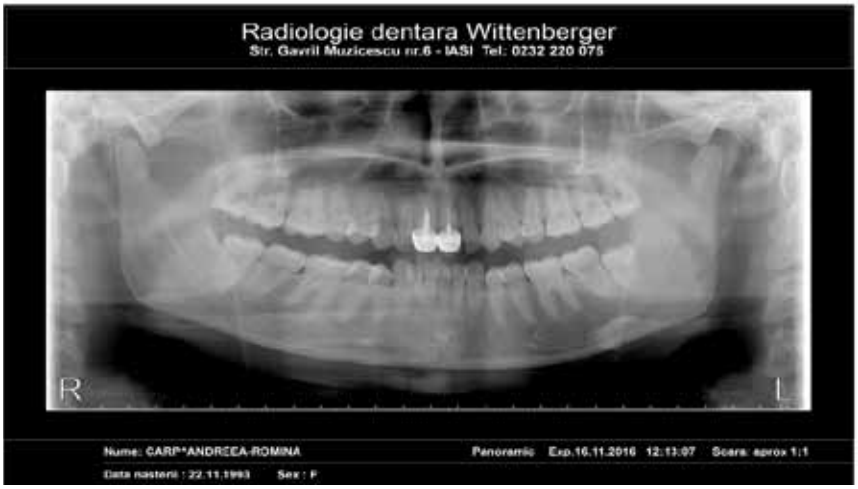

Fig. 2. Initial orthopantomography of the patient

Fig. 3. Presence of a gray coloration at the level of the proximal ridge of the second premolar 45

Fig. 4. Opening of the caries process at the level of the proximal ridge

indication of the presence of a carious lesion. The tooth was asymptomatic, but surgical treatment was indicated by opening the caries process by removing the proximal ridge using the turbine-mounted spherical bur.

The decayed dentin was then removed with a round steel bur mounted on a low-speed counter-angle. Removal of decayed tissue was performed from the periphery to the center of the lesion to minimize the risk of infection in case of pulpal exposure (Fig. 4).

After excavating the tooth substance affected by caries, the caries detector was applied to the cavity (fig.5). The cavity was stained with a Sable Seek indicator, produced by Ultradent, USA to determine the presence of residual decayed dentin after excavation. For this purpose, a sufficient amount of material was applied to the cavity and left to act for 10 seconds, then the cavity was washed with an abundant amount of water. After air drying, the cavity was examined to detect colored dentin sites.

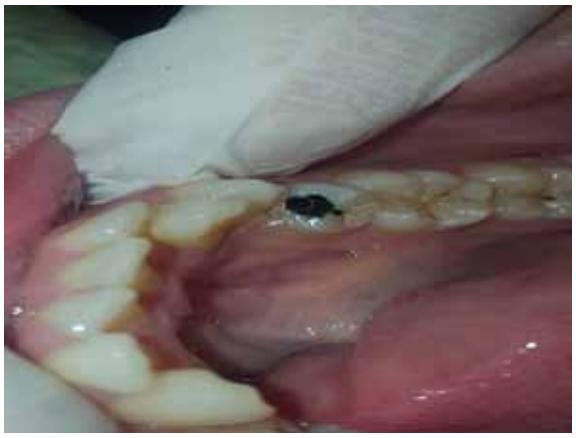

Fig. 5. Applying the caries detector to check if any infected dentin remained in the cavity

Fig. 6. The dye remained fixed at the cavity, which indicates the presence of the remaining infected dentin (dark green)

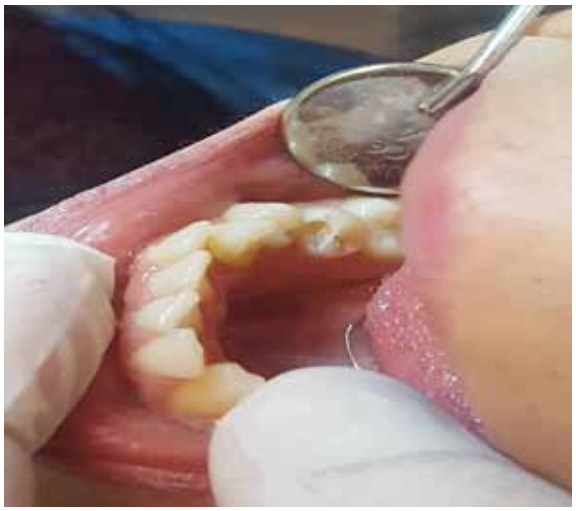

Fig. 7. Application of calcium hydroxide for remineralization and pulpal protection

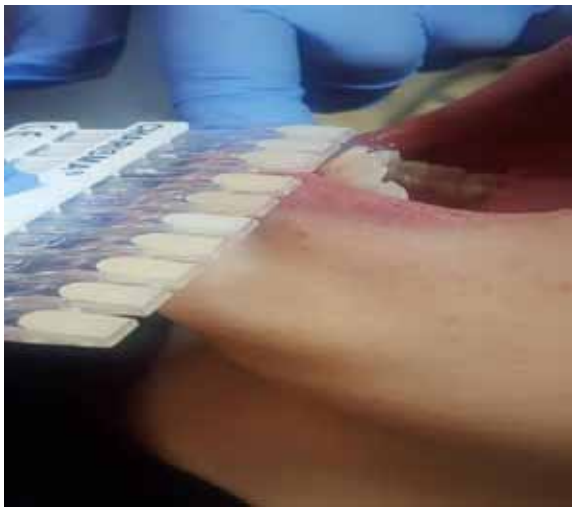

Fig. 8. Choosing the color of the teeth and the composite

The application of the caries detector dye indicated that the infected dentin remained cantoned mainly at the base of the cavity. The more intense staining indicated that the dentin is infected (dark green) (fig.6).

The remaining infected dentin was removed and calcium hydroxide was applied for remineralization (fig. 7).

Regarding the shade of the teeth, the color determination was done in natural light with the help of the color guide (fig. 8).

The etching step consisted in applying 37% orthophosphoric acid on the prepared dental surfaces. The acid was left in the tooth for 15 seconds, then the tooth was rinsed well with water (fig.9)

The cavity was air dried, the adhesive was applied on the tooth (fig.10,11) and it was light-cured for 20 seconds.

The composite material (Premise, Kerr) was inserted in the cavity, shaped and light-cured for 20 s (fig. 12,13).

A second clinical case is an 18-year-old patient AM who presented for a dental check-up. A thorough cleaning of the dental surfaces was performed by professional brushing. The examination of the dental surfaces was performed by visual and conventional radiological examination. Orthopantomography provided an overview of dental arches and dental lesions (fig. 14).

At the clinical examination performed with the help of the mirror and the dental probe, the gray coloration of the distal marginal ridge was observed in the first upper premolar 24, indicating the presence of a proximal caries (fig.15).

The opening of the carious process at the level of the proximal ridge was performed and

Fig. 9. Acid etching of the cavity

Fig. 10. Composite used for restoration (Premises, Kerr)

Fig. 11. Adhesive application and light curing for 20 s

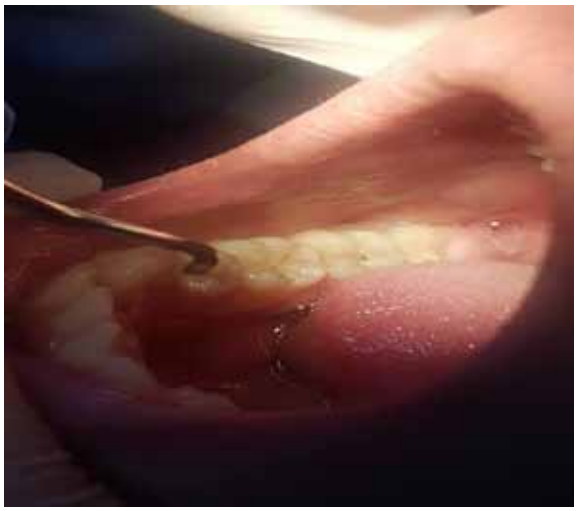

Fig. 12. Insertion of the composite in the cavity

the excision of the infected dentin (fig.16).

The application of the caries detector indicated that only the affected dentin remained on the gingival wall of the cavity (fig.17).

Less intense staining indicated that the dentin was affected and could be remineralized (light green) (fig.18). The dentin was left on the bottom of the cavity and calcium hydroxide was applied to remineralize it.

The cavity was then restored in a manner similar to the case described above.

RESULTS

Most of the areas of remaining carious dentin detected by the dye were located on axial, pulpal and lingual surfaces. In the clinical cases performed, the caries indicator remained fixed on the dentin of the cavity, but the color intensity was different. By observing the difference in staining intensity produced by the caries detector, it is possible to differentiate

Fig. 13. Final light curing for 20 s

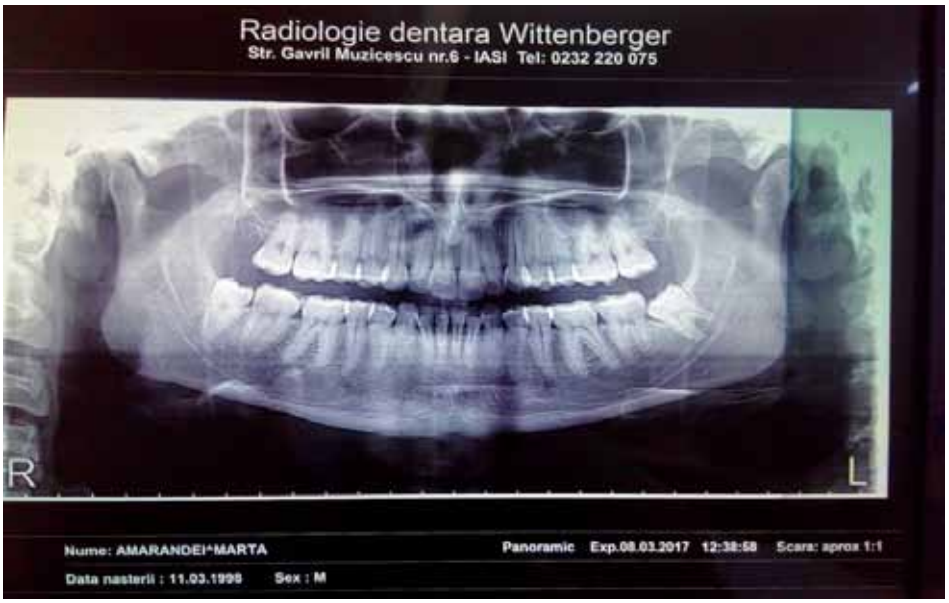

Fig. 14. Initial orthopantomography

Fig. 15. Coloration of the distal proximal ridge of the first upper premolar 24 indicating the presence of a carious lesion

Fig. 16. Opening of the carious process and excision of the infected dentin

Fig. 17. Application of the dye to check if there is still an infected dentin

Fig. 18. Fixing of the dye to the gingival wall (light green coloration indicates affected dentin)

between infected tissues with more intense staining and less intense staining of the affected tissue. Quantifying color intensity can give a measure of severely diseased tissue, and the obtained contrast can help identify the infected and affected dentin if tactile discrimination is not available.

With Sable Seek you can get this certainty, its dark green color avoids any confusion near the walls of the pulp, where red dyes are easily confused. In some cases the less mineralized affected dentin on the axial and pulpal surfaces was consciously left in place to reduce the risk of pulpal exposure.

DISCUSSIONS

Determining the complete removal of carious dentin by color (visual criteria) and hardness (tactile criteria) could lead to unnecessary excavation of healthy dentin or insufficient excavation of cavities (20). In addition, the excavation of caries by conventional methods using steel, tungsten or polymer burs leads to the formation of residual dentinal detritus and, by this means, non-specific dyes for detection could cause unintentional staining of the smear layer (21). When caries indicator dye is used, the infected dentin is stained the color of the dye. Non-infected dentin can be stained if it is demineralized due to its higher porosity, due to which dye molecules can penetrate the tissue. Thus, demineralized dentin is stained, but with a much lower intensity compared to carious dentin (22).

However, dyes that reveal disintegration do not prove to be specific for caries lesions, but also to stain healthy circumpulpal dentin and healthy dentin at the enamel-dentin junction, which have a lower natural mineral content and are relatively more porous (23,5), which leads to unnecessary removal of healthy dental structures (24). In order to preserve the dental tissue, the partially preserved and remineralizable underlying dentin is maintained (dentin affected by disintegration) (25,26). To remedy this dilemma, some authors have recommended leaving the tissue slightly stained, as this represents the affected dentin (8,27,28).

The use of a dye to detect carious lesions is still under discussion and even seems to be not reliable for some researchers (18,29,30). However, these dyes are clinically useful for the diagnosis and excavation of caries in many cases. When using a caries detector dye, dentin that is lighter than the color of the dye should not be removed to prevent excessive excavation (31,32). Sometimes it can be very difficult to determine the extent of this lighter color, especially in the deeper layers of dentin, which can define the healing process. It is not always easy to determine at what stage of dentin excavation should stop, as there may be a lack of clinical markers. This would lead to differences in the size of the cavity, the strength of the remaining hard dental tissue and the condition of the pulp. Therefore, there must be another objective marker in the removal of carious dentin (33). Caries-detecting dyes, which have been considered advances in diagnostic dentistry, have recently declined in popularity due to insufficient distinctive properties, such as staining of less mineralized circumpulpal and predentine areas (34) causing potential damage to pulpal tissue (26). Caries detector dye is significantly more effective than visual inspection and dental probe according to Fluckiger et al. (35).

The present study found that Sable Seek can be used as a complementary diagnostic tool and may be useful for less experienced practitioners to distinguish between infected and affected dentin based on the difference in staining intensity produced by the caries detector. The use of complementary diagnostic means after confirmation of the removal of caries by tactile examination can reveal possible areas of carious dentin in the prepared cavity and thus prevent future consequences.

CONCLUSIONS

The function of the caries detector is meant to distinguish by the intensity of the staining, the tissue to be removed and the tissue to be kept, in order to make a conservative treatment and to avoid the possible exposure of the pulp. The potential utility of this method of early diagnosis is to help prevent tooth decay. Thus, it can be concluded that the use of dyes for caries detection can complement conventional methods of caries detection by evaluating the extent of caries in the dentin. Caries tissue detection dyes are less expensive, available on the market and can be used effectively as complementary examinations at the dental chair.

REFERENCES

1. Roberson M, Heymann O. *Sturdevant's art and science of operative dentistry*. 5th ed. St. Louis : Mosby ; 2006. p. 308-11.
2. Iwami Y, Hayashi N, Yamamoto H, Hayashi M,Takeshige F, Ebisu S. Evaluating the objectivity of caries removal with a caries detector dye using color evaluation and PCR. *J Dent*. 2007 ; 35(9) : 749-54.
3. Thakre G, Reddy MG, Kulkarni M, Chaudhari S, Vidhale S. Histobacteriological evaluation of advancing front of carious dentin : Excavation done with and without using caries disclosing dye - A comparative in-vitro study. *J Dent Res Sci Develop*. 2015 ; 2 : 22-5.
4. Anderson MH, Loesche WJ, Charbeneau GT. Bacteriologic study of a basic fuchsin caries-disclosing dye. *J Prosthet Dent* 1985 ; 54 : 51-5.
5. Yip HK, Stevenson AG, Beeley JA. The specificity of caries detector dyes in cavity preparation. *Br Dent J* 1994 ; 176 : 417-21.
6. Ohgushi K, Fusayama T. Electron microscopic structure of the two layers of carious dentin. *Journal of Dental Research*. 1975 ; 54 : 1019-1026.
7. Fusayama T. Two layers of carious dentin ; diagnosis and treatment. *Operative Dentistry*. 1979 ; 4 : 63-70.
8. de Almeida Neves A, Coutinho E, Cardoso MV, Lambrechts P, Van Meerbeek B. Current concepts and techniques for caries excavation and adhesion to residual dentin. *The Journal of Adhesive Dentistry*. 2011 ; 13 : 7-22.
9. Kidd EA. How 'clean' must a cavity be before restoration ? *Caries Res* 2004 ; 38 : 305-13.
10. Fusayama T. A simple pain-free adhesive restorative system by minimal reduction and total etching. Ishiyaku EuroAmerica Inc., Tokyo.1993, 23-45.
11. Ogawa K, Yamashita Y, Ichijo T, Fusayama T. The ultrastructure and hardness of the transparent layer of human carious dentin. *J Dent Res* 1983 ; 62(1) : 7-10.
12. Heymann HO, Swift EJ, Ritter AV, Sturdevant CM. Sturdevant's art and science of Operative Dentistry. In Dental caries : etiology, clinical characteristics, risk assessment, and management. (6th edtn), Elsevier/Mosby, St. Louis, Mo. 2013, 41-88.
13. Banerjee A, Kidd EA, Watson TF. In vitro evaluation of five alternative methods of carious dentine excavation. *Caries Research*. 2000 ; 34 : 144-150.
14. Ansari G, Beeley JA, Reid JS, Foye RH. Caries detector dyes--an in vitro assessment of some new compounds. *J Oral Rehabil*. 1999 Jun ; 26(6) : 453-8.
15. McComb D. Caries-detector dyes - How accurate and useful are they ? J Can Dent Assoc 2000 ; 66 : 195-8.
16. Horobin RW. How histological stains work. In : Suvarna SK, Layton C, Bancroft JD, editors. Bancroft's Theory and Practice of Histological Techniques. 7th ed. London : Churchill Livingstone ; 2013. p. 156-71.
17. Starr CB, Langenderfer WR. Use of a caries-disclosing agent to improve dental residents' ability to detect caries. *Oper Dent* 1993 ; 18 : 110-4.
18. Akbari M, Ahrari F, Jafari M. A Comparative Evaluation of DIAGNOdent and Caries Detector Dye in Detection of Residual Caries in Prepared Cavities. *J Contemp Dent Pract*. 2012 ; 13(4) : 515-20.
19. Kidd EA, Joyston-Bechal S, Beighton D. The uses of a caries detector dye during cavity preparation : a microbiological assessment. *British Dental Journal*. 1993 ; 174 : 245-248.
20. Gurbuz T, Yilmaz Y, Sengul F. Performance of laser fluorescence for residual caries detection in primary teeth. *Eur J Dent*. 2008 ; 2 : 176–84.
21. Otake S. The influence of the difference of caries detective methods on the bond strength for caries affected root canal dentin. *Kokubyo Gakkai Zasshi*. 2010 ; 77 : 20–6.
22. Uzunov TS, Uzunov T, Grozdanova R, Kosturkov D. Diagnosis of Dentin Caries – Ultraviolet Fluorescence. *Acta Medica Bulgarica*, 2014 ; 41(2) ; 55-60.
23. Banerjee A, Kidd EA, Watson TF. In vitro validation of carious dentin removed using different excavation criteria. *Am J Dent* 2003 ; 16(4) : 228-30.
24. Celiberti P, Leamari VM, Imparato JC, Braga MM, Mendes FM. *In vitro* ability of a laser fluorescence device in quantifying approximal caries lesions in primary molars. *J Dent*. 2010 ; 38 : 666–70.
25. Milia E, Pinna R, Castelli G, Bortone A, Marceddu S, Garcia-Godoy F, Gallina G. TEM morphological characterization of a one-step self-etching system applied clinically to human caries-affected dentin and deep sound dentin. *Am J Dentistry.* 2012, 25(6) 321-326.
26. Tak O, Usumez A. Diffusion of HEMA through human carious and non-carious dentin *in vitro*. *J Prosthodont*. 2013 ; 22 : 184–9.

27. Hamdi H, Hamama, Cynthia K.Yiu, Michael F. Burrow. Caries Management : A Journey between Black's principals and Minimally Invasive Concepts. *Int J Dentistry Oral Sci,* 2015 ; 2(8) : 120-125.
28. Iwami Y, Shimizu A, Narimatsu M, Kinomoto Y, Ebisu S. The relationship between the color of carious dentin stained with a caries detector dye and bacterial infection. *Oper Dent* 2005 ; 30(1) : 83-89.
29. Javaheri M, Maleki-Kambakhsh S, Etemad-Moghadam S. Efficacy of Two Caries Detector Dyes in the Diagnosis of Dental Caries. *J Dent (Tehran),* 2010 ; 7 : 71–76.
30. Peskersoy C, Turkun M, Onal B. Comparative clinical evaluation of the efficacy of a new method for caries diagnosis and excavation. *J Conserv Dent* 2015 ; 18 : 364–368.
31. Unlu N, Ermis RB, Sener S, Kucukyilmaz E, Cetin AR. An in vitro comparison of different diagnostic methods in detection of residual dentinal caries. *Int J Dent*. 2010 ; 2010 : 864935.
32. Fusayama T. Clinical guide for removing caries using a caries-detecting solution. *Quintessence Int*. 1988 Jun ; 19(6) : 397-401.
33. Banerjee A, Watson TF, Kidd EA. Dentine caries : take it or leave it ? *SADJ : Journal of the South African Dental Association = Tydskrif Van die Suid-Afrikaanse Tandheelkundige Vereniging*. 2001 Apr ; 56(4) : 186.
34. Thomas CC, Land MF, Albin-Wilson SM, Stewart GP. Caries detection accuracy by multiple clinicians and techniques. *Gen Dent* 2000 ; 48 : 334–8.
35. Fluckiger L, Waltimo T, Stich H, Lussi A. Comparison of chemomechanical caries removal using Carisolv or conventional hand excavation in deciduous teeth in vitro. *J Dent*, 2005 ; 2 : 87-90.

Corresponding author

Călin Dorelia Lucia, Assistant Professor, DMD, PhD
"Grigore T. Popa" University of Medicine and Pharmacy – Iași, Romania
Email: dorelia.lucia@gmail.com
Tel:+40728019779