Vol. XVIII – Nr. 2 – 2019 ORIGINAL PAPERS

INTRADUCTAL PAPILLOMA – IMAGISTIC ASPECTS

Manuela Ursaru[1], A.H. Nedelcu[2*], C.I. Stan[2], Paloma Manea[3], Irina Florea[4], D. Negru[1], Irina Jari[1]
"Grigore T. Popa" University of Medicine and Pharmacy, Iasi
1. Department of Surgery II
2. Department of Morfofunctional Science I
3. Department of Medical I
4. Departament of Immunology

INTRADUCTAL PAPILLOMA – IMAGISTIC ASPECTS (Abstract): Introduction: Breast papillary lesions are rare epithelial tumors with various imaging features. The study aims to assess the contribution and limitations of imaging methods useful in the diagnosis of this pathology. Material and method: Over a period from March 1st to December 31st 2018, 64 patientswho have clinically presentedspontaneous, clear or bloody nipple discharge underwent imagistic evaluation (ultrasonography, mammography, MRI). Results: The solitary papilloma was diagnosed in 32 cases with retroareolar location, and in one case with peripheral location. Multiple peripheral lesions (intraductal papillomatosis) were detected in 23 patients. Conclusions: Breast ultrasound with selective evaluation of lactiferous ductsis the most useful imaging method in the diagnosis of intraductal papillomatosis. Mammographic aspects are various and atypical. **Key-words**: INTRADUCTAL PAPILLOMA, BREAST ULTRASOUND, MAMMOGRAPHY.

INTRODUCTION

The intraductal papilloma is an epithelial proliferative benign tumor with an incidence of 3-4%, affecting women aged between 35 and 70 years (1). Depending on the location, there are two types of intraductal papillomas: central and peripheral. In the central form, the lesion is located in the subareolar region, often unique (intraductal solitary papilloma), characteristic for the perimenopausal period. In the peripheral form, the lesions are multiple (intraductal papillomatosis), located in the terminal ductal-lobular unit.

Juvenile papillomatosis occurs in women younger than 30 years of age and is associated with other benign breast lesions (2-4).

While the central form does not associate cellular atypia and presents the same risk of mammary neoplasia as fibrocystic changes, the peripheral form is predisposing tobreast cancer requiring surgical excision (2,5).

The imaging methods used in the diagnosis and surveillance of intraductal papillomas are: ultrasound (including Doppler), galactography, digital mammography, MRI (6).

MATERIAL AND METHOD

We retrospectively analyzed 64 patients between March 1st and December 31st, 2018, who clinically presented spontaneous, clear or bloody nipple discharge. All of the patients were evaluated by ultrasound (including Doppler mode), mammography being performed only in patients over the age of 40 years. Only two patients needed MRI assessment. Screening tools required were: a Philips Affiniti 70 G ultrasound system using an 18 MHz linear array transducer, a GE digitally mamography (Senographe Essential) unit and an MRI equipment Philips.

RESULTS

All the patients included in the study were examinated by ultrasound, with selective evaluation of lactiferous ducts. The imaging findings encountered were ductal ectasia with or without the hypo-/hyperechoic solid nodule, a well-defined intraluminal mass, clearly attached to the duct wall. Color Doppler evaluation revealed vascularity within the lesion (fig. 1). In 8 cases (12.5%), complete intraluminal oblit-

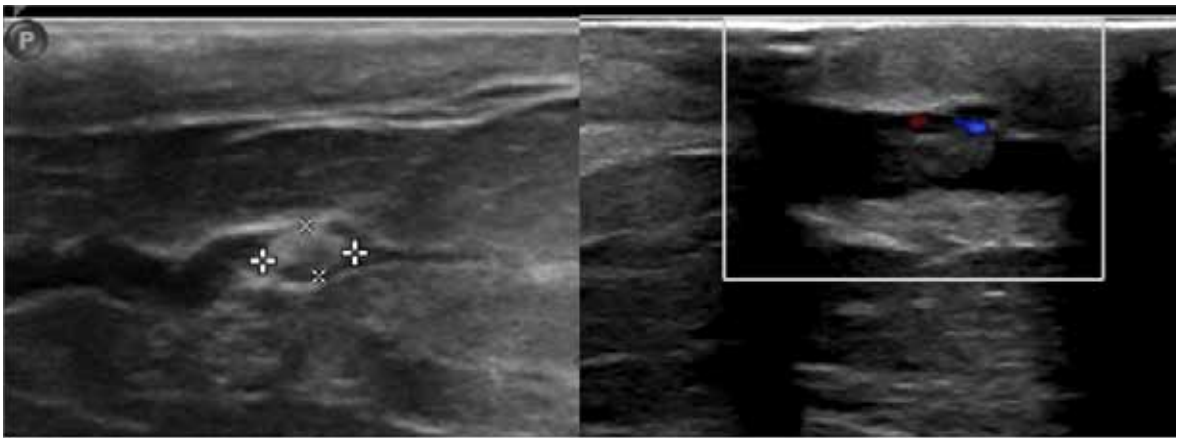

a b

Fig. 1. Intraductal papilloma: a. Ultrasound image shows a solid nodule in dilated duct. b. Color Doppler image reveals vascularity within the lesion.

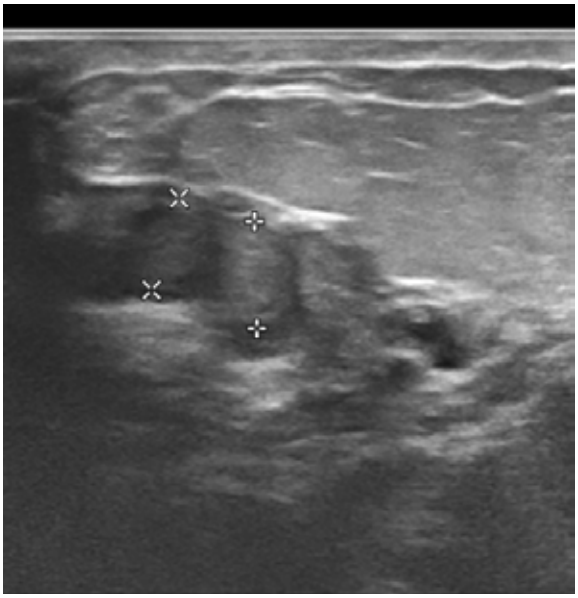

Fig. 2. Intraductal papillomatosis. Ultrasound image shows a dilated duct filled with hyperechoic material.

eration was detected only by hyperechoic material, without nodular aspect or Doppler signal (fig. 2). In 32 cases (50%) the lesion was unique, localized in the retroareolar region (fig. 3). In only one case (1.56%) was found an unique lesion, peripherally located, 7 cm from the nipple. Multiple peripheral lesions (papillomatosis) were detected in 23 patients (35.93%) under 40 years of age.

The mammographic examination was performed in 37 patients, those under 40 years of agenot having indication for this method. Mammography has highlighted various aspects. In 54% of cases (20 patients), when a single, small papilloma was detected by ultrasound, mammography was normal (BIRADS 1). 18.91% of cases (7 patients) shownretroareolar asymmetry, due to intraductal lesion or ductal ectasia (BIRADS 3). In 27% of cases (10 patients), mammography revealed a dense breast without being able to individualize focal lesions (BIRADS 0). Benign microcalcifications were detected in approximately 15% of cases. Two patients with a heredocolateral antecedents of maternal breast cancer, where the ultrasound had raised suspicion of papillary carcinoma, performed breast MRI. In both cases, the ultrasound detected a solid mass with crenulated contour, 1-1.5 cm in diameter, with intense Doppler signal, which is located in a retroareolar cystic structure. The MRI exam infirmed the suspicion of malignancy.

DISCUSSION

The patients included in the study were aged between 25 and 65 years and they addressed to the physician for unilateral nipple discharge, the diagnosis of intraductal solitary papilloma being established in 64% of cases (fig. 4).

Breast ultrasound was the most useful imaging method in the diagnosis of intraductal papilloma, which revealed solid lesions with a diameter of 2-15 mm (4,6,7). Using mild local compression, the Doppler evaluation and the time elapsed since the last breastfeeding, it allowed differentiation of a lesion with ductal parietaloriginfrom an organized sediment/intraductal hematoma.

Being age-dependent, mammography was useful in a small amount of cases, revealing only focal density asymmetries and sometimes associated microcalcifications.

The presence of benign microcalcifications in this pathology is justified by the association

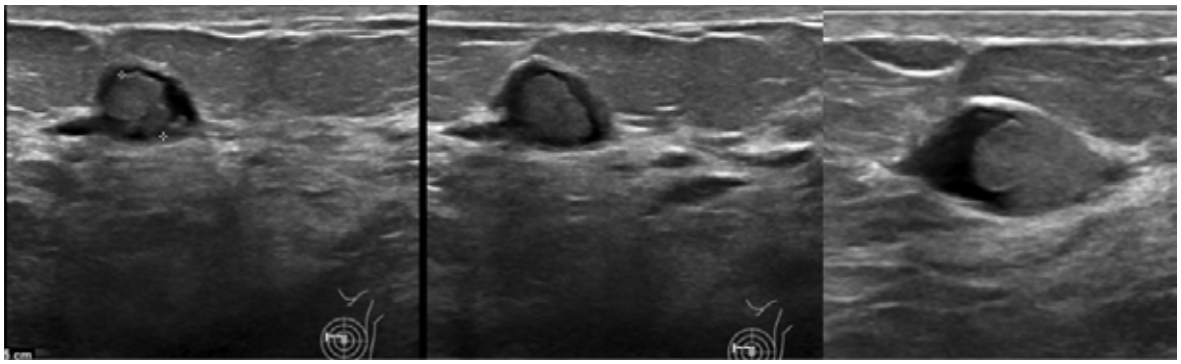

a b c

Fig. 3 (a,b,c). Intraductal papilloma. Ultrasound images reveal a dilated lactiferous duct occupied by a solid mass with crenulated contour.

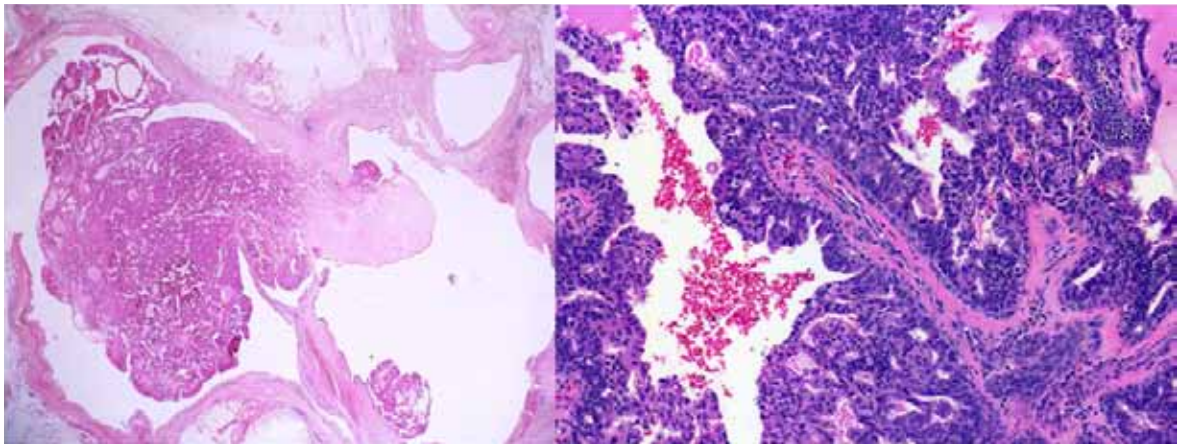

Fig. 4. Intraductal papilloma - Epithelial intraductal proliferation formed by 2 layers of cells (luminal and myoepithelial cells), localized on two conjunctive-vascular axis, with reduced focal cyto-nuclear atipia ; no necrosis is present.

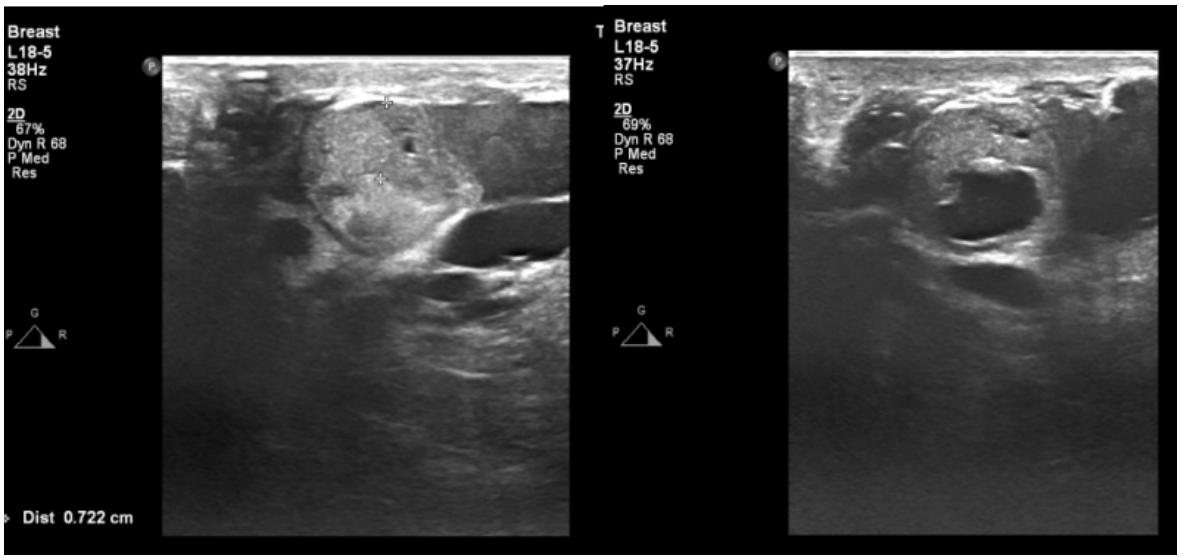

a b

Fig. 5. Intraductal papilloma. Ultrasound images reveal a dilated lactiferous duct with a solid mass and blood in different stages of degradation. a. longitudinal section b. transverse section.

of papillomas with hemorrhage, fibrosis or infarction (fig. 5).

Differentiation between microcalcifications from typical papillomas and pleomorphic microcalcifications from atypical papillomas is difficult, but essential for benign or malignant diagnosis (1,4,8).

The study revealed that 36% of cases had multiple intraductal papillomas. Intraductal papillomatosis, although less common than the solitary papilloma, is clinically asymptomatic, without nipple discharge,at most being detected a palpable nodule in the breast periphery. Treatment of these cases is surgical, given the association with invasive carcinoma in 20-30% of cases (2,9).

CONCLUSIONS

Breast papillary lesions are epithelial tumors with various imaging aspects and a difficult differentiation of benign or malignant character. Ultrasonographyis the most useful imaging method in the diagnosis of intraductal papilloma, including the Doppler evaluation. Mammographic aspects are not typical, but may sometimes associate microcalcifications that help assess the benign or malignant nature of the lesion.

REFERENCES

1. Brookes MJ, Bourke AG.Rodiological appearances of papillary brest lesions. *Clin Radiol* 2008 ; 63 : 1265-1273.
2. W Al Sarakbi, D Worku, PF Escobar, and K Mokbel. Breast papillomas : current management with a focus on a new diagnostic and therapeutic modality. *Int Semin Surg Oncol*. 2006 ; 3 : 1.
3. Mulligan AM, O'Malley FP. Papillary lesions of the breast : a review. *Adv Anat Pathol* 2007 ; 14 : 108-119.
4. Malai Muttarak, Pailin Lerttumnongtum, Benjaporn Chaiwun , Wilfred Peh. Spectrum of Papillary Lesions of the Breast : Clinical, Imaging and Pathologic Correlation. *AJR* 2008 ; 191(3) : 700-707.
5. Adil Aljarrah, Kamran Ahmad Malik, Husam Jamil, Zoheb Jaffer,Sukhpal Sawhney, and Ritu Lakhtakia. Diagnostic dilemmas in Intraductal papillomas of the breast - Experience at Sultan Qaboos University Hospital in the Sultanate of Oman. *Pak J Med Sci*. 2015 Mar-Apr ; 31(2) : 431–434.
6. Riham Eiada, Jennifer Chong, Supriya Kulkarni, Frank Goldberg, Derek Muradali. Papillary lesions of the breast- MRI, ultrasound and mammographic appereances. *AJR* 2012 ; 198(2) : 264-271.
7. V. Tarallo, E. Canepari, and C. Bortolotto. Intraductal papilloma of the breast : A case report. *J Ultrasound*. 2012 Jun ; 15(2) : 99–101.
8. Karakas C, Resetkova E, Sahin aa. Lésions papillaires du sein. Dans : JP de Palazzo, éditeur. Diagnostics difficiles en pathologie de sein. *LLC de publications médicales de démos*, New York, 2011 : 56-87.
9. Doshi DJ, March DE, Crisi GM, Coughlin BF. Complex cystic breast masses : diagnostic approach and imaging-pathologic correlation. *Radiographics*. 2007 Oct ; 27 Suppl 1 : S53-64.

**** Corresponding author***

Alin Horatiu Nedelcu
e-mail: alin_nedelcu@yahoo.com